

FUE Clinical Practice Guidelines

Developed by the International Society of Hair Restoration Surgery Follicular Unit Excision Advancement Committee (FUEAC)

Authors (alphabetical): Márcio Crisóstomo, MD, FISHRS, Kapil Dua, MBBS, MS, FISHRS, Aditya K. Gupta, MD, PhD, FISHRS, Parsa Mohebi, MD, FISHRS, Robert H. True, MD, MPH, FISHRS, and Ken L. Williams, Jr. DO, FISHRS

FUEAC Chair and Primary Editor: James A. Harris, MD, FISHRS

FUEAC Members and Co-Editors: Conradin von Albertini, MD, FISHRS, Christian N. Bisanga, MD, Jean Devroye, MD, FISHRS, O. Tayfun Oguzoglu, MD, and Arthur Tykocinski, MD, FISHRS

Disclaimer: These guidelines are provided for educational and informational purposes only. They should not be interpreted as setting a standard of care, or be deemed inclusive of all proper methods of care, nor exclusive of other methods of care. Following these guidelines will not ensure successful treatment in every situation. Each individual physician should make an independent judgment regarding the proper treatment of each patient based on the particular facts and circumstances. These guidelines are provided “as is.” The International Society of Hair Restoration Surgery (ISHRS) makes no representation or warranty as to their accuracy or completeness. The guidelines reflect the best available data at the time they were prepared. Future studies may yield results that require revisions to the recommendations in this guideline to reflect new data.

The Follicular Unit Excision Advancement Committee (FUEAC) of the International Society of Hair Restoration Surgery has written this treatise on Follicular Unit Excision (FUE) in which suggestions for the safe practice of this harvest method are provided. It was authored and reviewed by the committee and the suggestions were based on any available studies as well as the combined experience and expertise of the committee members. It is intended to provide basic information on the harvest technique for any physician performing FUE.

One of the most controversial aspects of FUE is the improper delegation of the excision aspect of this procedure to non-physicians and non-licensed medical providers. It is the position of the ISHRS that “such procedures [FUE] must be performed by a properly trained and licensed physician. Physicians who perform hair restoration surgery must possess the education, training, and current competency in the field of hair restoration surgery. It is beyond the scope of practice for non-licensed personnel to perform surgery. Surgery performed by non-licensed medical personnel may be considered practicing medicine without a license under applicable law.”

It is the recommendation of the FUEAC that FUE must be performed by properly trained and licensed physicians and appropriately licensed and trained Nurse Practitioners and Physician Assistants working under the laws of that state and/or country. Acknowledging the position of the ISHRS, and at the same time recognizing that in some locales unlicensed health care staff may perform FUE, this document will refer to properly trained, licensed or non-licensed individuals legally performing FUE as a “non-physician clinician,” or NPC. In the opinion of the FUEAC, it goes against the patients’ interests and is medically unsound when individuals without a health care license perform FUE surgery, even if it might be legal in certain countries or states.

CHAPTER I: PATIENT EVALUATION FOR FUE CANDIDACY

Aditya K. Gupta, MD, PhD, FISHRS

1. SELECTION OF CANDIDATES

A. Medical History

- i. Age of patient
 1. Avoid performing FUE on young patients (< 25 years old) as the extent of future hair loss is difficult to predict. This significantly impacts the assessment of the safe donor area (SDA).¹⁻³
- ii. Gender of patient
 1. If patient meets all required candidacy criteria, FUE can be considered in both males and females.⁴
- iii. Type and degree of hair loss
 1. If a patient meets all required candidacy criteria, FUE can be considered in male patients with Norwood scores of II to VII. The use of body hair can be considered in advanced patterns.^{4,6}
 2. FUE can be considered in female patients with diffuse thinning as long as they have an acceptable miniaturization rate.^{4,6}
- iv. Current treatments to prevent hair loss
 1. It should be noted that the continued use of medical treatments does not mean an aggressive harvesting of the donor zone should be conducted.^{8,13}
- v. Previous hair transplant procedures
 1. If a limited number of grafts have been previously harvested with strip or FUE and the patient meets all other candidacy requirements, then sequential sessions/procedures are possible.
 2. If FUE will cause overharvesting, that is, visible thinning in the scalp donor zone, then additional FUE sessions using scalp donor hair is not recommended.¹⁴

B. Evaluate Hair and Desired Transplant Location

- i. Assess density of donor and recipient areas.
 1. Use a handheld densitometer in multiple locations in the donor zone to obtain density.¹⁷
 2. Examine the donor and recipient areas for factors that could influence donor density such as the presence of scars and dermatologic conditions (e.g., alopecia areata, psoriasis, scarring alopecia).
 3. The presence of diffuse un-patterned alopecia (DUPA) may be a relative contraindication as it may result in a severely depleted appearance of the donor area.
 4. Assess hair direction, color, angle, caliber, and curl of hair in both the recipient and donor areas as these factors can impact the appearance of hair density.^{13,18,19}
- ii. Evaluate if non-scalp regions are suitable donor and/or recipient areas
 1. Examine the beard and moustache areas first as they typically have higher amounts of hair in the anagen phase, which are more likely to survive the transplant than telogen hair.^{24,25}
 2. Focus your assessment on patches of body hair that are noticeable and can be seen from a distance as they are likely to make a cosmetically significant difference once transplanted.²⁵
 3. Use the torso donor index to determine if chest hairs are suitable; if a patient scores below a 4, chest hair should not be used.²⁶

2. PATIENT EXPECTATIONS

A. Patient's Hair Length Expectations

- i. Inform the patient of the shaving options associated with each FUE technique, indicating that their hair would need to be trimmed to approximately 1mm in length.
- ii. If the patient wants to keep their hair length, discuss the use of non-shaven or preview long hair FUE techniques with them.^{32,33}

B. Scarring Possibilities

- i. Inform the patient that FUE is not a scarless surgery; pinpoint scarring (hypopigmentation) is likely to occur and will be more prominent in patients with Fitzpatrick IV-VI skin types as compared to patients with Fitzpatrick I-III skin types.³⁴
- ii. Inform the patient that FUE scarring will reflect light differently than surrounding skin, making hypopigmentation much more noticeable when hair is cut short.³⁴
- iii. As punch size and overharvesting may influence scar appearance, discuss the possibility of splitting the procedure into multiple FUE sessions instead of one large session.³⁴⁻³⁶

3. FUE VS. FUT

A. Relative Contraindications for FUE

- i. Patients with a narrow safe zone
 1. FUE should be considered carefully in patients with a narrow safe zone as there is a limited region of hairs presumed to be permanent.

2. Donor area depletion could be a possibility in patients with narrow safe zones and requiring a high number of grafts.
- ii. Patients with advanced baldness
 1. If transplanting body hair is not possible, patients requiring a large number of grafts should be counseled as to the limits of grafts available and scalp coverage.³⁹
 2. Strip harvesting, a combination of strip (FUT) and FUE, body hair donor, and/or non-surgical methods may be a better alternative for these patients.

B. Presentations Where FUE May Be Preferred Over FUT

- i. FUE can be used as a corrective procedure when repairing plugs or inappropriately placed grafts.²⁰
- ii. FUE can be used in patients with scars that cannot be excised such as patients with noticeable linear scarring or burns.⁴⁶
- iii. FUE is the preferred option for patients with limited or no scalp laxity.
- iv. FUE is the preferred method for body hair graft harvest.

CHAPTER II

DONOR AREA EVALUATION AND MANAGEMENT

Márcio Crisóstomo, MD, FISHRS

The donor area evaluation is a fundamental part of the FUE procedure, since it defines the limitations, cosmetic results, possible contraindication to the procedure, expected number of grafts, and the coverage possible.

A correct evaluation of donor area characteristics will help define the surgical plan.

1. DONOR AREA EVALUATIONS

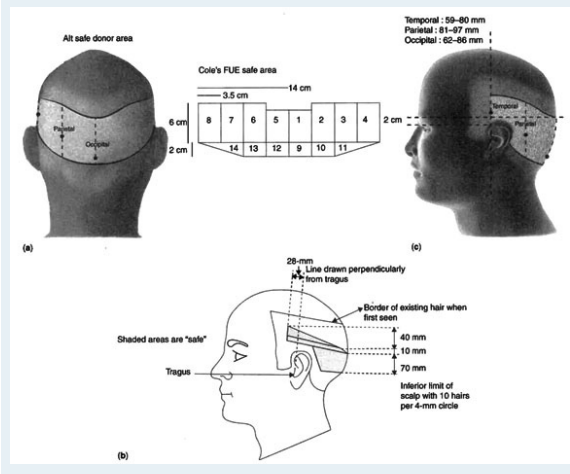
A. Determination of the Safe Donor Area (SDA)

- i. Ideally, all grafts should be removed from the SDA to decrease the risk of obtaining impermanent hairs.
- ii. It is hard to determine the real safe zone, especially in younger patients.
- iii. Careful family history and physical examination of the scalp can help determine the SDA.
- iv. Assess the patient for the possibility of retrograde alopecia and avoid harvesting from the area at risk.
- v. A relatively safe assumption is that every young patient could turn into a Norwood Class VI in the future. Figure 1 depicts a father and son as an example of the extent of future hair loss.
- vi. Some authors have proposed safe zones as exemplified in Figure 2 (Source: Devroye, J. An Overview of the Donor Area: Basic Principles. In: Unger, et al., eds. *Hair Transplantation*, 5th Ed., p. 258).
- vii. In larger sessions of FUE, it's believed that surgeons may cross the limits of the safe zone, harvesting grafts

FIGURE 1. Possible extent of future hair loss that needs to be considered.

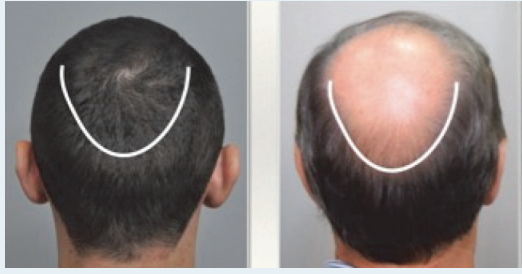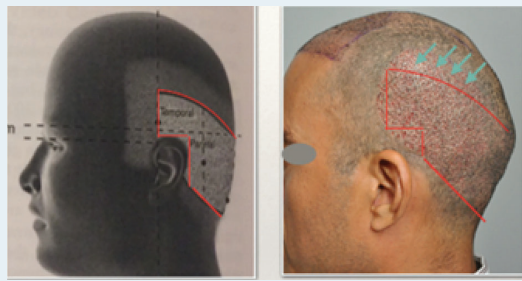


FIGURE 2. The “safe” donor zone as proposed by Alt (upper left), Cole (upper right), and Unger (lower).



from the edge or even outside the real safe zone (blue arrows in Figure 3). If the surgeon knows that this will happen in a given surgery, the patient should be informed of the benefits of this (to have more hair for a period of time) and the possible consequences for the long term (to lose some hairs harvested from an unsafe zone and possible visible punctiform white scars).

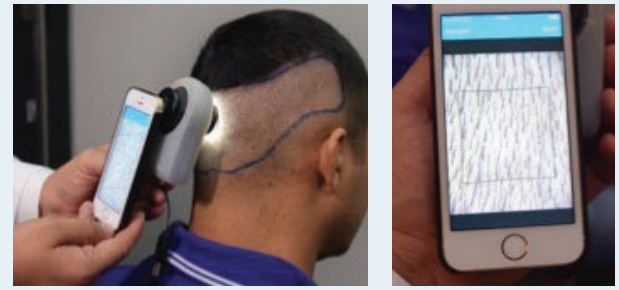
FIGURE 3. Grafts extracted outside the “safe” zone (blue arrows).



B. Determination of Hair Density

- The knowledge of hair density is to aid the surgeon in anticipating how many grafts can be safely excised.
- The use of a densitometry to evaluate the patient's scalp average hair and follicular unit density should be performed when planning the surgery.
- Measurements can be taken from the temporal, mastoid, and occipital areas as it varies according to the area.
- A photo of 1cm² is taken from the above mentioned areas and the number of follicular units/hairs is counted. Usually the density varies from 60 to 100 FU/cm². (See Figure 4.)

FIGURE 4. Densitometer is used to determine hair and follicular unit density (left). The photos can be seen on a phone camera (right).



C. Measurement of the Caliber of Hair and Hair Quality

- Hair caliber is another important variable when planning a hair transplant procedure and can be measured by a precision digital micrometer or thickness gauge (Figure 5).

FIGURE 5. Digital micrometer for measuring hair shaft diameter (left); thickness gauge for measuring hair shaft diameter (right).



- Terminal hairs are divided into the following:

FIGURE 6. Hair shaft thickness categories.

	Diameter (micrometers)
Fine hair	60 to 65
Medium hair	65 to 80
Coarse hair	80 and above

- Thicker hair usually produces a denser appearance after transplantation, but it can also impact the coverage of the donor area as the hair is removed.
- Other characteristics of hair that should be assessed that can impact transplant results include color, straight/curly, Afro-textured (tight curl), Asian (straight, wide caliber), and hair/scalp color contrast.

D. Calculations

- With the defined limits of safe donor area identified and hair density and hair caliber measured, some calculations can be made.
- The hair diameter index (HDI) or hair coverage value (HCV) can be used as a guide. These values are obtained from the product of the average hair shaft diameter and the number of hairs/cm². The HDI is calculated as hairs/cm² caliber (μm)/100 and the HCV as hairs/cm² × caliber (mm). The calculated values differ by a factor of 10.¹⁻⁴
 - It is suggested that adequate scalp coverage is maintained by only removing the number of follicular units that will leave a residual HDI of 60 or greater or an HCV greater than 6.
- Graft excision limit in a non-harvested scalp without

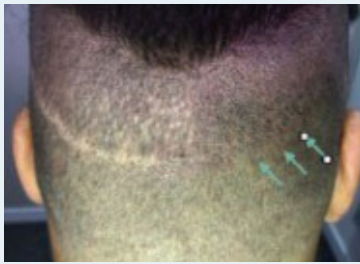visual depletion: as an approximation, removal of 40% to 50% of the follicles in a given area should not produce a visible depletion of the area. Caution must be exercised as this value will depend on factors such as hairs/follicular unit, hair shaft diameter, hair length, hair curl, hair color, and angle of hair emergence.

- iv. The surgeon should compare the information of how many grafts are needed for the transplant (recipient area size \times density proposed) with the total number of grafts that can be safely removed (donor area measurements \times hair density \times 40%) for surgical planning.

E. Secondary Cases

- i. With one or multiple strip scars, there may be a reduction in donor capacity and this should be evaluated before surgery.

FIGURE 7. Scalp micropigmentation to diminish the visibility of a linear scar (blue arrows).



ii. Repair options for strip donor scars include scar revision with primary excision, implantation of grafts into the scar, or scalp micropigmentation (SMP) (Figure 7). The combination of these methods is possible and should be discussed with the patient.

- iii. Previous FUE surgeries:

Densitometry is fundamental in these cases along with an overall aesthetic evaluation of the donor area. It is important to avoid overharvesting and to identify areas with preexisting low density. It is also important to avoid harvesting follicular units next to FUE scars to prevent voids and the creation of areas of low-density.

injection will not be as effective. Concentrations of 1:150,000 to 1:300,000 are most commonly employed.

- ii. Through use of skin traction and pressure
 1. Stretching the skin taut or applying hand pressure can control localized bleeding.

C. Hair Shaving

- i. Correct length
 1. Most FUE procedures are performed with the hair shaved to between 0.5 and 1.5mm long.
- ii. Full shave
 1. The entire donor zone can be shaved as this will facilitate excision site dispersion and enhance efficiency.
- iii. Micro strip or zone shave
 1. If a series of small scalp FUE procedures are planned, micro strips or zones may be shaved in the donor area, which will then be covered during healing by adjacent hair.
 - a. Low-density harvest advised with this approach to avoid creating thin appearing patches in the donor region.
 - b. The location of these strips or zones must be changed with each subsequent procedure.
 - c. Patients must be advised these “zones” may be visible if the hair is cut too short.
 2. This method of donor preparation should not be performed on any patient that might wear their hair short (less than 10 to 12mm) at some point. Limit this preparation to women, men who have had previous strip surgery, or older males who have no intention of wearing their hair short.

CHAPTER III GRAFT HARVEST

Robert H. True, MD, MPH, FISHRS

1. PREPARATION FOR HARVEST

A. Achieve Anesthesia

- i. The targeted harvest area must be anesthetized prior to beginning the graft harvest using local anesthetic (LA). A combination of short-acting and long-acting LA agents is recommended for harvests that will take over one hour.
- ii. Because the harvest area is usually larger than strip surgery, great care must be taken to calculate safe doses and avoid exceeding the limits of any anesthetic agent.

B. Ensure Hemostasis

- i. Through use of safe concentrations and amounts of epinephrine solutions
 1. Injecting dilute epinephrine and saline solution into the superficial dermis, throughout the harvest field, is advised to control bleeding during harvest. Deep

D. No Shave Techniques

- i. General
 1. When performing FUE without shaving:
 - a. Direct punch or low speed oscillation is helpful as punch rotation tends to tangle adjacent hair, particularly with motorized rotation.
 - b. When using rotation, the punch may be stopped when moving hairs out of the way of target units.
 - c. Adjacent hair should be held flat to avoid hair tangling and avulsion.
 - d. Harvesting from inferior to superior aids visualization and systematic excision.
 - e. These are highly advanced procedures and not advised for beginners.
- ii. Pre-trimming
 1. If performing FUE without shaving, the donor area is marked and prepared by selecting and trimming the targeted follicles with scissors. It is recommended to do this the day before the procedure as it is very time consuming.
- iii. No trimming
 1. Grafts can be excised without pre-trimming.
 - a. The hairs in the targeted FU are usually cut by the punch during excision but may remain

intact. This is generally performed with sharp punches.

b. Going slowly is a necessity.

iv. Preview long hair¹

1. Window or slot punches allow the long hairs to be held in the punch during excision, which keeps them intact for performing preview long hair transplantation.

E. Map Grid in Donor Region and Set Limit of Excisions per Grid Area

- i. Mapping a grid in the donor region is recommended as it facilitates an even distribution of excisions and limits the risk of overharvesting. Determine the target number of grafts and the number of grids (4 to 8cm²), then the number of targeted excisions per square centimeter. Not all grids will have the same density of excisions due to variations in follicular density.

F. Proper Positioning

- i. Critical to a successful and efficient harvest
- ii. With the patient recumbent:
 1. The surgeon is best seated or standing at the top or to the side of the top of the patient's head.
 2. The assistant is positioned to the side of the patient's head opposite the surgeon's dominant hand.
 3. The patient lies:
 - a. Prone for harvesting the occiput
 - b. Prone with head rotated to the side for harvesting the parietal areas
 - c. Lateral decubitus for harvesting the temporal zones
 - d. Supine with neck extended or lateral decubitus for beard harvesting
 - e. Supine, lateral decubitus, or prone for body harvest
 4. The patient is elevated to a level that the surgeon's vision with loupes is comfortable without neck strain and eyes are aligned to see the hair emergence angle.
- iii. Patient sitting
 1. The surgeon is best seated behind or to the side of the patient so that the eyes are level with or slightly below the harvest zone.
 2. One assistant will sit or stand beside the surgeon.
 3. One or two assistants may stand toward the front of the patient and place grafts as they are being harvested.
 4. The patient will be sitting with his/her back to the surgeon. An assistant may hold the head stable.

2. GRAFT EXCISION EQUIPMENT

A. General Principles

- i. All equipment and punches must be fully cleaned and sterilized.
- ii. Punches with an intact edge can be reused if cleaned and re-sterilized.
- iii. In some locations, single-use equipment is required by regulation.

- iv. Equipment designed for single use, such as tubing collection canisters and some punches, should not be reused.
- v. Knowing more than one FUE technique or device increases ability to deal with the widest variety of situations.
- vi. Having backup equipment protects against having to abort a procedure.

B. Manual Technique

- i. Employs a handle and sharp punch.
- ii. Direct method is pushing the punch into the skin without rotation.
- iii. Oscillation method is performed by rotating the punch back and forth between the thumb and index fingers as it enters the skin.
- iv. Precise depth control is required and customized.
 1. Typical initial dissection depth is 2.0 to 3.0mm.
- v. The UPunch Curl™ for Afro textured hair does not require rotation but a curved insertion and dissection motion to follow the curl of the follicles.

C. Motorized Sharp

- i. Settings must be customized.
- ii. Perform test grafts at beginning and throughout procedure.
- iii. Use lowest RPM (revolutions per minute) that cuts without skin distortion.
- iv. Typical initial settings
 1. Insertion depth 2.0 to 3.0mm
 2. 1,000 to 2,000 RPM
- v. One-stage punch insertion

D. Motorized Hybrid

- i. Settings must be customized.
- ii. Perform test grafts at beginning and throughout procedure.
- iii. Typical initial settings:
 1. 50- to 60-degree arc of oscillation
 2. 70 to 80 oscillations per minute
- iv. Two stages of punch insertion
 1. Hold punch firmly and stationary until epidermis incised.
 2. Let punch work itself deeper—do not push.
 3. Slow punch oscillation to a stop upon reaching desired depth.
- v. Insertion depth commonly 3.5 to 4.0mm, sometimes more

E. Motorized Blunt

- i. Settings must be customized.
- ii. Perform test grafts at beginning and throughout procedure.
- iii. Typical initial settings
 1. 4.0 to 5.0mm insertion depth (ethnicity dependent)
 2. 1,000 to 1,500 RPM
- iv. Two stages of punch insertion
 1. Hold punch stationary but firmly at angle until epidermis incised (engagement).
 2. Advance the punch to desired depth.

F. Robotic Assisted

- i. Settings must be customized.
- ii. Tensioner must be positioned and adjusted correctly.
- iii. Punch insertions must be monitored by surgeon.
- iv. Settings of the sharp punch depth, dull punch depth, punch size, and targeting pattern are determined by surgeon or by assistant with direct orders from surgeon.

3. GRAFT EXCISION TECHNIQUE

A. Use Skin Tension

- i. By the surgeon
 1. The hand not holding the punch is used to pull the skin taut, which helps reduce skin distortion, reduce transections, and facilitate excision.
 2. The direction of traction is typically opposite the direction of hair growth.
- ii. By the assistant
 1. The assistant can use both hands pulling in opposite directions to create counter-traction, which is even more effective.
- iii. By the surgeon and assistant
 1. The surgeon's hand pulls superiorly and the assistant's inferiorly to create counter-traction.
- iv. By tension devices
 1. The ARTAS Robot employs a tensioning ring.
 2. Attaching stretched tubing or a surgical glove to the scalp with staples provides another way to create traction.

B. Administer Superficial Tumescence

- i. Deep tumescence in large fields is not as effective as tumescence given into the superficial dermis locally just before an area is harvested.
- ii. The degree, amount, and location of tumescence ultimately will depend on the FUE device being utilized and the physician's experience to obtain the best quality grafts with the type of punch being utilized.
- iii. Combining this with traction/counter-traction greatly aids excision.

C. Determine Correct Punch Insertion Depth (*depth with minimal transections and removal without force*). *This differs according to punch type and patient skin type.*

- i. Sharp
 1. Initial setting 2.0 to 3.0mm
 2. Adjust according to test grafts.
 3. Monitor and adjust throughout different donor regions based on continuous observation of graft quality and extraction forces.
- ii. Blunt
 1. Typically dissect to the full punch depth of 4.0 to 5.0mm.
 2. Adjust according to test grafts.

3. Monitor and adjust throughout different donor regions based on continuous observation of graft quality and extraction forces.
- iii. Hybrid
 1. Initial setting 3.0 to 3.5mm
 2. May go as deep as 4.0 to 5.0mm.
 3. Adjust according to test grafts.
 4. Monitor and adjust throughout different donor regions based on continuous observation of graft quality and extraction forces.

D. Determine Correct Punch Centering and Insertion Angle

- i. Place the point where the target hairs emerge from the skin in the center of the punch.
- ii. Observe hair exit angle with high power loupes.
- iii. Initial punch insertion angle should be 10 to 20 degrees greater than observed exit angle.
- iv. Observe grafts for transections and adjust.

E. Determine Correct Punch Diameter

- i. Use smallest diameter punch that produces grafts with minimal transection, splay, denuding of follicles, and follicle paring.
- ii. Most common diameters between 0.8mm and 1.0mm

F. Adjust Technique by Recognition of Follicle Variables

- i. Curve
 1. With sharp punch, adjust for curve with shallower insertion, larger punch, and/or arcing movement.
 2. With blunt or hybrid punch, adjust for curve with slight arc or punch size.
- ii. Extreme curl
 1. With sharp punch, use larger diameter, careful depth limit, and arcing insertion or convert to blunt or hybrid.
 2. With blunt or hybrid punch, use larger punch or arcing movement.
 3. With all punch types, center target follicle toward front (hair emergence is the obtuse angle) edge of punch.
- iii. Splay
 1. Use a loupe magnifier for inspection of test grafts and measurement of location and degree of splay.
 2. Set sharp punch insertion just above point of splay or use larger diameter punch.
 3. With blunt or hybrid punches, this is usually not a challenge, but if it is, use a larger diameter punch.
- iv. Recognize and adjust for donor architecture
 1. For patients with complex donor area, perform partial harvest from sections of follicular groups that least disrupt the donor hair architecture.

4. GRAFT REMOVAL EQUIPMENT

A. Forceps Types

- i. Serrated
 1. Grips the tissue, but may cut into it with too much pressure.
- ii. Smooth

1. May slip from the tissue and then crush if squeezed too firmly.
- iii. Diamond crusted
 1. Grips the tissue without cutting or slipping.
- iv. ATOE (Aide to Extraction)
 1. Specialized forceps for pulling grafts that allows several grafts to be gathered at a time
- v. Straight vs curved forceps
 1. Both may be used for initial grasp of graft just below epidermis.
 2. Curved is preferred for grasping graft below bulge.

B. Removal Technique

- i. Single forceps
 1. Should be applied just below the epidermis and above the bulge.
 2. Is only possible if graft is deeply incised.
 3. Can produce high rate of capping.
- ii. Double forceps
 1. First forceps placed just below epidermis and graft slightly elevated.
 2. Second forceps applied below bulge.
 3. Graft removed by pulling with both forceps simultaneously.
 4. Extraction possible at shallower incision depth.
 5. Reduces capping.
- iii. Triple forceps
 1. Same as the double-forceps method but second person pushes the skin downward with the forceps as the two forceps pull upward.
 2. Overcomes tethering even better than the two-forceps method.
- iv. ATOE plus forceps
 1. Grafts lifted with forceps applied just below epidermis and gathered into ATOE applied below the bulge. Extraction is accomplished by pulling with both forceps and ATOE.
- v. Traction and counter-traction
 1. When grafts are difficult to pull, having an assistant stretch the skin in opposite directions with two hands makes the extraction easier.

C. Correct Use of Suction

- i. Suction substitutes for forceps in the extraction phase of follicular unit excision.
- ii. Suction can be used to elevate the graft during excision allowing a shallower punch insertion depth.
- iii. Suction can be used to remove the graft once it has been excised
 1. To accomplish this, punch must be inserted deeply.
 2. Since sharp punches are used, deep penetration risks higher transection rates. Extreme care must be taken to ensure grafts are not dried and desiccated because of the suction.

5. ANCILLARY EQUIPMENT

A. Proper Magnification and Illumination

- i. Surgical loupes in the range of 4.5 to 8.0 are recommended.

- ii. Loupe working distance of 200 to 400mm is most ergonomic.
- iii. Addition of an LED light to the loupes improves visualization.

B. Use of Sterile Punches Only

- i. If punch sterility is broken during the case, it should be replaced with a new sterile punch.

6. ROLES OF THE SURGICAL TEAM

A. Surgeon

- i. Performs all incisions (unless delegated to a non-physician clinician).
- ii. May delegate graft removal (extraction) from the skin.
- iii. Routinely monitors assistants extracting and processing grafts.

B. Assistants

- i. Are fully trained in safe graft handling.
- ii. Remove grafts incised by the surgeon.
- iii. Maintain graft hydration during all phases of handling.
- iv. Perform microscopic inspection and sorting of grafts.

CHAPTER IV GRAFT EVALUATION AND MANAGEMENT

Ken L. Williams, Jr. DO, FISHRS

1. GENERAL

A. Graft Evaluation

- i. Comparing grafts: fatty (strip harvest) versus skeletonized (FUE)
 1. Grafts created using stereomicroscopic dissection after strip excision possess a greater amount of enveloping fat that surrounds the vital structures of the follicle such as the connective tissue sheath, external and internal roots, bulge, and dermal papilla (DP).
 2. FUE grafts typically possess less enveloping fat and are commonly referred to as "skeletonized grafts," which are sensitive to desiccation and repetitive placement injuries.
 3. Smaller punch diameters typically produce grafts that have less investing fat and tissue, which may impact graft quality and survival if the grafts are handled without careful attention.
- ii. Defining transection
 1. Follicle transection is defined by any microscopic or visible fracture of the follicle.
 2. Transected follicles are more susceptible to graft growth failure or poor growth.
 3. Transected grafts can be recorded and categorized as partial or complete transection.
- iii. Intraoperative use of microscope
 1. The stereomicroscope remains the best graft evaluation device.

2. Stereomicroscopic evaluation of the grafts can be used to assess the Graft Quality Index (GQI) as described by True.
- iv. Monitoring graft quality
 1. The monitoring and recording of graft quality are typically done by a technician.
 2. The graft quality assessment and transections recording can be performed on every excised graft or on samples.
 3. Operative factors impacting follicle growth and survival
 - a. Physical damage to the grafts caused by dehydration, transection, or blunt trauma during the extraction and implantation of grafts
 - b. Ischemia-reperfusion injury (IRI), storage medium, and out of body time of the grafts
 4. Follicle damage should be analyzed and reported to the physician so that any necessary changes in the dissection equipment, instrumentation, or technique may be instituted as soon as possible.
 5. Graft transection recording can be performed on every excised graft or on samples.

B. Graft Handling

- i. Stresses encountered by follicles
 1. Minimize graft "out-of-body" time to decrease IRI to the grafts.
 2. Bio-enhanced holding solutions and culture media may decrease IRI.
- ii. Graft placement-technician training and experience
 1. Properly trained technicians or medical assistants must gently and efficiently place the grafts in the recipient sites.
 2. Repetitive Placement Trauma (RPT) negatively impacts graft survival and cosmesis. RPT occurs after numerous unsuccessful attempts to place the grafts, and the goal is to place grafts in a single insertion attempt.
 3. The epidermis of the harvested graft can be removed by the properly trained technician. If the graft epidermis is not removed by the technician after harvesting, the graft should be placed such that the epidermis is about 0.5 to 1.0mm above the scalp surface.
- iii. Effect of drying or desiccation
 1. FUE harvested grafts can be at greater risk for desiccation because of the decreased volume of perifollicular fat.

2. SPECIFIC TOPICS

A. Graft Preservation (enhanced storage solutions with buffering, osmotic balance, nutrients, and liposomal ATP may enhance graft survival)

B. FUE Graft Dissection (Trimming, removing hair fragments, fat, epidermal cap)

- i. Trimming of FUE grafts to remove surrounding fat should be avoided.
- ii. Hair fragments from harvested grafts represent frac-

tured follicles and should be removed under the microscope prior to implantation.

- iii. The epidermal cap (EC) can be removed under the microscope. If the EC is not removed, the grafts must occupy a position 0.5mm above the dermal surface to reduce scalp defects such as cobble stoning, pitting, and scar tissue reaction.

C. Graft Splitting (*ex vivo* and *in vivo*)

- i. *Ex vivo* splitting of complex grafts under a stereomicroscope is standard of care if and when additional single follicles are needed for the hair restoration procedure.
- ii. Complex family groupings may be isolated, incised, and extracted *in vivo* in a pattern that removes only a portion of the follicular groupings. This manner of harvesting leaves behind melanin-containing follicles in the scalp to reduce hypopigmentation.

D. Ergonomics in Evaluation and Management

- i. Serious complications from poor ergonomic application in a hair transplant procedure occur. They apply to both the patient and physician during FUE donor harvesting. The ergonomics of FUE can increase the risk for musculoskeletal injury especially to the physician operator.
- ii. The physician and patient are exposed to prolonged periods of time during donor harvesting that can impact underlying or preexisting musculoskeletal diseases.
- iii. FUE requires substantial musculoskeletal energy, prolonged static and stationary positions. Harvesting can last up to 6 to 8 hours for the novice surgeon attempting large FUE cases (>2,000 grafts).
- iv. FUE donor harvesting requires physical exertion, so intermittent rest periods during FUE donor harvesting are recommended.
- v. The use of robotic FUE naturally reduces ergonomic injuries to physicians.

3. QUALITY CONTROL MEASURES

A. Transection Rates (TR)

- i. Vary from one physician to another. Constant monitoring of the TR during FUE donor harvesting is critical for successful graft growth. The final growth yield from transected grafts is lower than grafts without fractures or damage within the follicular unit. It is important to minimize follicle transection rates; striving for a rate less than 10% would be prudent.

B. Average Hairs per Graft

- i. an important concept in determining the possible cosmetic outcome to the hair transplant procedure as more hair shafts equate to greater visual hair density.

C. Missing Grafts

- i. A concept that is defined by the inability of the operator to identify a graft, follicles, or a skin cap after a scoring attempt has been made. The rate of "missing grafts" should be as low as possible as an increased rate results in excessive and unnecessary donor scarring.

CHAPTER V

FUE GRAFT IMPLANTATION

Parsa Mohebi, MD, FISHRS

1. PLACING TECHNIQUES

A. Forceps

- i. Forceps placement requires excellent manual dexterity to attain good transplant outcomes. Poor forceps placement technique can result in poor outcomes as the FUE grafts are susceptible to repetitive placement trauma (RPT) and desiccation.
- ii. Considerations
 1. Grasping the graft at the bulb may cause damage and affect survival (Figure 8).
 2. Grasping above the bulbs may cause bending of the follicles during insertion and result in a "J" hook deformity that may impact graft survival (Figure 9).

FIGURE 8. Grasping the follicles above the bulb results in a bent distal hair shaft.

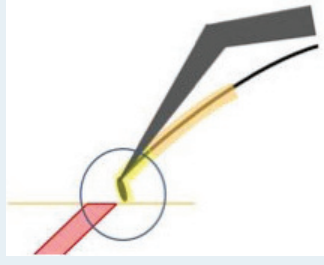
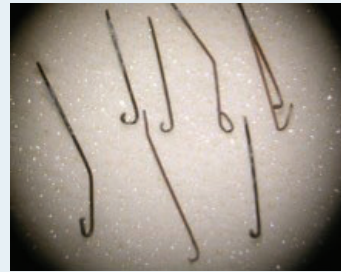

FIGURE 9. "J" hook deformity of retained hairs with a bent distal shaft.



3. Since the hair on FUE grafts is usually trimmed short, determining the curvature of hair growth can be a challenge. The first attempt can be to identify direction of the hair shaft curl. The second is that the sebaceous glands tend to be on the acute side of hair emergence.
4. To minimize trauma to the FUE grafts, consider the "no-touch" technique where the recipient site is dilated or enlarged with a needle, probe, or a small hook. The graft is then grasped from the epidermis only and inserted without the forceps touching the follicles at any location.

B. Implanter

- i. Implanters have a plunger, and when depressed, a stylus will push the graft out of the device into the recipient site. These devices allow grafts to be placed easily and with high efficiency without the risk of RPT. The technique of using implanters is easily learned and can minimize the over-manipulation of the grafts, prevent hook formation, and prevent dehydration if performed properly.
- ii. Which implanter to choose: the type of implanter chosen for the procedure depends on several factors such as the physical space, the number of technicians, and the feasibility of having multiple operators working on a patient's scalp at the same time.

1. Sharp Implanter
 - a. The implanter tip is sharp and enables the surgeon to create the recipient site and implant the grafts in sequence. The grafts are typically loaded into the implanters by the technicians. The typical implanter needle has a thin wall and slot that allows the grafts to be pulled into the lumen of the implanting needle.
 - b. The surgeon should not delegate the use of sharp implanters to unlicensed medical providers.
2. Blunt Implanter
 - a. The blunt or dull needle implanter can either be created by blunting or dulling the sharp leading edge of the needle or can be purchased blunt. It is specifically intended to place grafts into pre-made recipient sites, and this task can be delegated by the surgeon to any qualified staff member.

C. Placer

- i. Grafts are loaded into a blunt needle-like device with a channel either by use of forceps to drag the graft into the lumen or by rolling the channel over the graft to insert it onto the lumen. This is followed by inserting the non-sharp tip into a pre-made recipient site and then forceps are used to slide the graft into the recipient site.

D. Inserter

- i. A combination type of implanter/placer¹ that allows loading grafts like a placer and a mechanism for placing the graft into the pre-made recipient site similar to an implanter.

2. CONCLUSIONS

- i. Safe handling of the grafts is crucial to the outcome of a hair transplant procedure. The use of implanters or placers is encouraged to minimize graft trauma.
- ii. When choosing the method of implantation, the surgeon should consider the arrangement of the procedure in terms of the number of technicians available and whether the grafts will be implanted while extraction is in progress. Simultaneous extraction and placement of the grafts allows for a reduction in the time that the grafts stay out of the body.

CHAPTER VI

POSSIBLE FUE SEQUELAE

Kapil Dua, MBBS, MS, FISHRS

1. HYPOPIGMENTED SCARS IN THE DONOR AREA

A. Cause

- i. They occur because of the removal of the melanin-bearing hair follicle and skin and the subsequent secondary intention healing.
- ii. They can appear as atrophic white scars at the donor site, often as large as 1.5mm in diameter.

- iii. They are more prominent in patients with darker skin than in patients with fair skin.
- iv. They become more visible in patients with shorter hair, especially if the donor area has been overharvested.

B. How to Minimise the Appearance of These Scars

- i. Use smaller sized punches (0.8 to 0.9mm).
- ii. Avoid excising adjacent grafts.
- iii. In high density excisions, excise alternate grafts in zig-zag fashion to prevent coalescence of white dots and avoid the appearance of donor area thinning.
- iv. Consider the use of ACell in the donor sites (although this is not proven to prevent this).
- v. Use sub-follicular unit harvesting to leave hair behind immediately adjacent to the excision site

C. Management

- i. Scalp micropigmentation (SMP)
- ii. Keep the hair longer to cover the hypopigmented excision sites.

2. MOTH-EATEN/PSEUDOSYPHILITIC APPEARANCE

A. Cause

- i. It occurs due to excessive graft removal in non-adjacent areas.
- ii. This condition may become visible and more prominent in short hair style or when the head is shaved.

B. Avoidance

- i. How to minimise the moth-eaten appearance:
 - 1. Properly space excisions to ensure that there is hair emerging superior to the excision site to “cover” the extraction site.
 - 2. Excise in a zigzag manner to provide uniformity and to avoid linear gaps.
 - 3. Diffuse excision sites in a uniform distribution.

C. Management

- i. Scalp micropigmentation
- ii. Keep the hair longer hair to cover the moth-eaten appearance.

3. DONOR AREA EFFLUVIUM

A. Cause

- i. Iatrogenic, unknown etiology
- ii. Possible interruption of the blood supply from overharvesting or excisional trauma due to large punch size
- iii. Excessive use of epinephrine

B. How to Minimize the Chances of Donor Area Effluvium

- i. Avoid the removal of consecutive grafts (high density excision).
- ii. Keep excision densities less than 30 grafts/cm².
- iii. Use the smallest punch size possible.

C. Management

- i. Will usually resolves in 3 to 4 months without intervention.

- ii. Consider topical steroids or 5% minoxidil.

4. BURIED GRAFTS

A. Cause

- i. Occurs when the punch is inserted into the dermis without proper engagement (incision of the skin by the punch) and the follicle is pushed inside the dermis and embedded.
- ii. Most commonly seen when using blunt punches.

B. How to Avoid Buried Grafts

- i. Allow adequate time for the punch to engage (incise) the skin.
- ii. Use any markings on the punch to provide a visual clue of engagement.

C. Management

- i. Attempt removal of the buried grafts by putting pressure on the surrounding skin or exploring the wound.

5. FOLLICULITIS OF THE DONOR AREA

A. Cause

- i. High percentage of transected follicles remain buried in the dermis
- ii. Buried grafts as described above

B. How to Avoid Folliculitis

- i. Minimize transections.
- ii. Remove buried grafts.

C. Management

- i. Use topical and systemic antibiotics for few days.
- ii. Incision and drainage or removal of the retained follicles, if required.

6. NECROSIS OF THE DONOR AREA

A. Causes

- i. Microvascular trauma
- ii. Interruption of the blood supply by high density extractions or the insertion of punches too deeply
- iii. Excessive use of high concentration epinephrine

B. How to Minimize the Chances of Necrosis of Donor Area

- i. Avoid overharvesting.
- ii. Use the smallest punch size possible.
- iii. Insert the punch to the minimal depth required to remove the graft.

C. Management

- i. Use proper antibiotics after culture sensitivity.
- ii. Consider the use of nitroglycerin paste.

7. OVERHARVESTING/THINNING OF THE DONOR SCALP

- i. Appears as visible thinning with patches of hair loss

A. Cause

- i. When large numbers of follicular units are removed

and often associated with high follicle transection rates

1. High probability that the transected hairs do not regenerate, and if they do, their caliber is less than compared to the original hair.
2. Increased microvascular trauma to the donor area
3. A lower percentage of anagen hairs as they have been selectively removed
4. Reduced caliber of the hair shaft

B. How to Avoid Overharvesting

- i. Avoid high-density excisions (greater than 10 to 15 grafts/cm²) in a single session.
- ii. Assess the donor area follicular unit density and hair quality and adjust the excision density.

C. Management

- i. Scalp micropigmentation (SMP)
- ii. Keep longer hair to cover the thinned donor area.
- iii. Implant follicular units into the donor area (which can be harvested from body or scalp, if possible).

8. HARVESTING OF GRAFTS THAT ARE AT AN INCREASED RISK OF FUTURE LOSS

A. Cause

- i. When grafts are harvested from outside the safe zones, especially in younger patients with ongoing process of hair loss, these grafts may be lost over time.
- ii. This usually occurs when grafts are taken from the upper and lower margins of the donor region.
- iii. In the donor area, it can lead to white dots in the crown area, which will become visible as the balding area advances.

B. How to Avoid It

- i. Confine the excisions to the best estimate of the safe donor zone.

C. Management

- i. Scalp micropigmentation in the area where white dots are present
- ii. Implant more grafts if available from the body.

REFERENCES

CHAPTER I

1. Reed, W. Co-editors' Messages. *Hair Transplant Forum Int'l*. 2012; 22(6):215-216.
2. Mysore, V. *Hair Transplantation*, 1st Ed. New Delhi, India: Jaypee Brothers Medical Publishers; 2016. pp. 185-220.
3. Ruston, A. "Red Flags" in Hair Restoration Surgery. In: *Hair Transplantation*, 5th Ed. Informa Healthcare; 2011, pp. 76-81.
4. Jindal, O. Selection of Patients in FUE. In: *FUE Hair Restoration Major Procedures Minor Incisions*. Cosmazone Pvt. Ltd.; 2012, pp. 17-21.
5. Knudsen, R. The challenge of FUE in women. *Hair Transplant Forum Int'l*. 2014; 24(4):150.
6. Saxena, D. FUE Hair Transplant in Women. In: *FUE Hair Restoration Major Procedures Minor Incisions*. Cosmazone Pvt. Ltd.; 2012, pp. 141-144.
7. Yates, W. FUE in Patients of African Descent: Pearls and Pitfalls. In: *Hair Transplant 360: Follicular Unit Extraction (FUE)*, 4th Ed. Jaypee Brothers Medical Publishers (P) Ltd; 2016, p. 349.
8. Knudsen, R. What would hair restoration surgery be like if we didn't have finasteride? *Hair Transplant Forum Int'l*. 2015; 25(5):200.
9. Kaufman, K.D., et al. Long-term treatment with finasteride 1mg decreases the likelihood of developing further visible hair loss in men with androgenetic alopecia (male pattern hair loss). *Eur J Dermatol EJD*. 2008(Aug); 18(4):400-406.
10. Mella, J.M., et al. Efficacy and safety of finasteride therapy for androgenetic alopecia: a systematic review. *Arch Dermatol*. 2010(Oct); 146(10):1141-1150.
11. Price, V.H., E. Menefee, and P.C. Strauss. Changes in hair weight and hair count in men with androgenetic alopecia, after application of 5% and 2% topical minoxidil, placebo, or no treatment. *J Am Acad Dermatol*. 1999(Nov); 41(5 Pt 1):717-721.
12. Saxena, K. Pre-Operative Phase. In: *FUE Hair Restoration Major Procedures Minor Incisions*. Cosmazone Pvt. Ltd.; 2012, pp. 35-45.
13. Saxena, K. Follicular Unit Extraction: Logic, Case Selection and Indications. In: *Hair Transplantation*, 1st Ed. Jaypee Brothers Medical Publishers; 2016, pp. 185-189.
14. Dua, K., A. Dua, and M. Chahar. Repeat Hair Transplant. In: *Hair Transplantation*, 1st Ed. Jaypee Brothers Medical Publishers; 2016, pp. 293-303.
15. Lorenzo, J. FUE Complications and Difficult Situations. In: *Hair Transplant 360: Follicular Unit Extraction (FUE)*. Jaypee Brothers Medical Publishers (P) Ltd; 2016, p. 340.
16. Nordstrom, R. Classification of Androgenetic Alopecia. In: *Hair Transplantation*, 5th Ed. Informa Healthcare; 2011, pp. 37-39.
17. Lam, S., and J.K. Williams. *Hair Transplant 360: Follicular Unit Extraction (FUE)*. Jaypee Brothers Medical Publishers (P) LTD; 2016, pp. 15-36.
18. Saxena, D. Assessment of Donor Area. In: *FUE Hair Restoration Major Procedures Minor Incisions*. Cosmazone Pvt. Ltd.; 2012, pp. 23-28.
19. Rajput, P. Assessment of Recipient Area. In: *FUE Hair Restoration Major Procedures Minor Incisions*. Cosmazone Pvt. Ltd.; 2012, pp. 30-34.
20. Saxena, D. Importance of Second Session in FUE Hair Restoration. In: *FUE Hair Restoration Major Procedures Minor Incisions*. Cosmazone Pvt. Ltd.; 2012, pp. 163-168.
21. Garg, A., and S. Garg. Design of Hairline. In: *Hair Transplantation*, 1st Ed. Jaypee Brothers Medical Publishers; 2016, pp. 241-247.
22. Khanna, M., and V. Purohit. Recipient Area Planning, Preformed Slit and Placement Technique of Implantation. In: *Hair Transplantation*, 1st Ed. Jaypee Brothers Medical Publishers; 2016, pp. 248-257.
23. Soni, S. Vertex Hair Transplantation. In: *Hair Transplantation*, 1st Ed. Jaypee Brothers Medical Publishers; 2016, pp. 331-337.
24. Saxena, K., and S.S. Savant. Body to scalp: evolving trends in body hair transplantation. *Indian Dermatol Online J*. 2017(Jun); 8(3):167-175.
25. Cole, J. Body to Scalp. In: *Hair Transplantation*, 5th Ed. Informa Healthcare; 2011, p. 305.
26. Mahadevia, B. Donors Other Than Scalp: Beard and Chest. In: *Hair Transplantation*, 1st Ed. Jaypee Brothers Medical Publishers; 2016, pp. 307-312.
27. Yun, S.S., et al. Hair diameter variation in different vertical regions of the occipital safe donor area. *Arch Plast Surg*. 2017(Jul); 44(4):332-336.
28. Dua, K., A. Dua, and M. Chahar. Facial Hair Transplantation. In: *Hair Transplantation*, 1st Ed. Jaypee Brothers Medical Publishers; 2016, pp. 313-320.
29. Rajendrasingh, R. Eyebrow Restoration. In: *Hair Restoration*, 1st Ed. Jaypee Brothers Medical Publishers; 2016, pp. 321-324.
30. Saxena, K., and D. Saxena. In: *FUE Hair Restoration Major Procedures Minor Incisions*. Gwalior (India): Cosmazone Pvt. Ltd.; 2012, pp. 18-20.
31. Saxena, K. Consultation. In: *FUE Hair Restoration Major Procedures Minor Incisions*. Cosmazone Pvt. Ltd.; 2012, pp. 12-15.
32. Avram, M.R., R. Finney, and N. Rogers. Hair transplantation controversies. *Dermatol Surg Off Publ Am Soc Dermatol Surg Al*. 2017(Nov); 43(Suppl 2):S158-62.
33. Cole, J., and C. Insalaco. State-of-the-art FUE: advanced

- non-shaven technique. *Hair Transplant Forum Int'l*. 2014; 24(5):161,166-169.
34. Boden, S., and K. Williams. Motorized FUE with Sharp Punch. In: *Hair Transplant 360: Follicular Unit Extraction (FUE)*. Jaypee Brothers Medical Publishers (P) Ltd; 2016, pp. 248-289.
 35. Boden, S. FUE Donor Evaluation and Surgical Planning. In: *Hair Transplant 360: Follicular Unit Extraction (FUE)*. Jaypee Brothers Medical Publishers (P) Ltd; 2016, pp. 109-119.
 36. ISHRS. Comparison Between Strip Harvesting & FUE—Part 1 [Internet]. International Society of Hair Restoration Surgery. 2015 [cited 2018 Feb 12]. Available from: <http://www.ishrs.org/article/comparison-between-strip-harvesting-fue-part-1>
 37. Knudsen, R. FUE and donor depletion. *Hair Transplant Forum Int'l*. 2013; 23(3):86.
 38. Thompson, J. Assessment and Management of the Patient with Body Dysmorphic Disorder. In: *Hair Transplantation*, 5th Ed. Informa Healthcare; 2011, pp. 84-85.
 39. Mishra, S. *Hair Transplant Surgery*, 1st Ed. Jaypee Brothers Medical Publishers Ltd.; 2014, pp. 86-96.
 40. Singh, M.K., and M.R. Avram. Technical considerations for follicular unit extraction in African-American hair. *Dermatol Surg Off Publ Am Soc Dermatol Surg Al*. 2013(Aug); 39(8):1282-1284.
 41. ISHRS. A comparison between strip harvesting and FUE hair transplants—part 2 [Internet]. International Society of Hair Restoration Surgery. 2015 [cited 2018 Feb 15]. Available from: <http://www.ishrs.org/article/comparison-between-strip-harvesting-fue-part-2>
 42. Tsilosani, A. Expanding graft numbers combining strip and FUE in the same session: effect on linear wound closure forces. *Hair Transpl Forum Int'l*. 2010; 20(4):121-123.
 43. Dua, K., A. Dua, and M. Chahar. Dos and Don'ts of Follicular Unit Extraction. In: *Hair Transplantation*, 1st Ed. Jaypee Brothers Medical Publishers; 2016, pp. 205-212.
 44. ISHRS. A comparison between strip harvesting and FUE hair transplants—part 3 [Internet]. International Society of Hair Restoration Surgery. 2015 [cited 2018 Feb 12]. Available from: <http://www.ishrs.org/article/comparison-between-strip-harvesting-fue-part-3>
 45. Dua, A., K. Dua, and R. Kothottil. Follicular Unit Extraction: Mega & Giga Sessions. In: *Hair Transplantation*, 1st Ed. Jaypee Brothers Medical Publishers; 2016, pp. 213-220.
 46. Patwardhan, N., and V. Kirane. Case Selection, Counseling, and Planning for Surgery. In: *Hair Transplantation*, 1st Ed. Jaypee Brothers Medical Publishers; 2016, pp. 119-123.

CHAPTER II

1. Harris, J.A. Application of the Hair Diameter Index (HDI) in Obtaining a Target Hair Density. Poster Presentation at the International Society of Hair Restoration 11th Annual Meeting, New York, New York, USA, October 2003.
2. Harris, J.A. Introduction of the Hair Volume Index (HVI) and Its Correlation to Subjective Visual Hair Density. Scientific Session Presentation and Poster Presentation at the International Society of Hair Restoration Surgery 11th Annual Meeting, New York, New York, USA, October 2003.
3. Harris, J.A. Biodiversity of Hair Shaft Diameters: A Statistical Analysis. Poster Presentation at the International Society of Hair Restoration Surgery 11th Annual Meeting, New York, New York, USA, October 2003.
4. Erdogan, K. Hair Coverage Index: <https://youtu.be/O-gu9rJZhiY>. PowerPoint presentation at the World FUE Institute Meeting, 2015.

CHAPTER III

1. Pitchon, M. Preview long hair follicular unit transplantation: an immediate temporary vision of the best possible final result. *Hair Transplantation Forum Int'l*. 2006; 16(4):113-115.

CHAPTER IV

1. True, R.H. Graft Quality Index: a morphologic classification of follicular unit excision (FUE) grafts. *Hair Transplant Forum Int'l*. 2018; 28(2):45-51.

CHAPTER V

1. Mohebi, P. A novel device to insert FU grafts into premade sites. *Hair Transplant Forum Int'l*. 2018; 28(4):146-148.